

MENISCUS TRANSPLANTATION IN THE RABBIT KNEE JOINT USING A DEEP FROZEN MENISCUS ALLOGRAFT- PATHOHISTOLOGICAL PICTURE

LEŠIĆ A*, SAVIĆ V**, KRSTIĆ N***, BUMBAŠIREVIĆ M* and TATIĆ V**

* Institute for Orthopaedic Surgery and Traumatology, School of Medicine, Belgrade, Yugoslavia ** Institute for Medical Research and Institute for Pathology Military Medical Academy, Belgrade, Yugoslavia ***Department of Radiology, Faculty of Veterinary Medicine, Belgrade, Yugoslavia.

(Received 4. April 2002)

The aim of the study was to assess the clinical, radiological and histological characteristics of deep frozen meniscal allograft for the rabbit knee.

Eighteen (18) New Zealand white rabbits were operated on both knees and evaluated at three time intervals: after 2 weeks (first group), 8 weeks (second group) and 36 weeks (third group). Left knees without meniscal transplantation, served as the controls.

Meniscal grafts obtained from other rabbits were stored in a deep freeze at -17 °C when required deep frozen menisci were thawed in sterile saline and transplanted in the place of the removed right medial meniscus of the experimental animal.

The general condition, operated knees and X-ray pictures were monitored. After sacrifice the meniscal allografts were histologically analyzed.

There were no adverse clinical and radiological pathological findings after transplantation, while in the control group changes were noted.

At histological evaluation, 2 weeks after transplantation the collagen fibers were not oriented and there was a low cell population. Vascularity was observed in the second group, with cell repopulation and young immature collagen fibers. In the third group at 36 weeks the collagen tissue was more mature, with significant cell repopulation.

We may conclude that deep frozen meniscal allografts show significant collagen remodeling and cellular repopulation. New menisci protect the underlying cartilage. Thus this procedure appears beneficial in cases where there is no possibility to reconstruct the meniscal lesion.

Key words: meniscus allograft, transplantation, knee, surgery.

INTRODUCTION

The significance of the meniscus in knee joint function and maintenance is very well established. The removal of the meniscus induces changes on contact surfaces (Fukubayashi *et al.*, 1980) and alterations in the distribution of force in the joint, resulting in osteoarthritis. It was noted that late results following total meniscectomy were not satisfactory as only 10%-15% of patients were without any discomfort or symptoms (Tapper and Hoover, 1969). These degenerative changes were particularly pronounced in concurrent and associated lesions of the meniscus and anterior cruciate ligament -LCA deficient knee (Thompson and Fu, 1999). Therefore, one should try to keep the meniscus preserved whenever it is possible. Thus, the method of choice in meniscal lesions is meniscal repair, whenever it is possible. (Verdonk, 1997). On the other hand, in earlier total meniscectomy or in the case of an extensive degenerative meniscal lesion, where reconstruction is not possible (80% of cases), transplantation of the meniscus is necessary (Kuhn and Woyts 1996, Verdonk 1997).

The aim of our experimental study was to obtain data about the process of cell repopulation, maturation of connective tissue in transplanted menisci and data about the knee joint cartilage in the operated knee. The evaluation was based on the analysis of macroscopic, radiological and patohistological features of the transplant. The rabbit knee was used as an experimental model. to obtain a time-sequenced histological picture during a 6 month period,

MATERIAL AND METHODS

Experimental animals

In our study 18 rabbits of the New Zealand breed, weighing 2-3 kg, were used. In all experimental animals, medial menisci of the right knees were replaced with deep-frozen meniscal allografts provided by total meniscectomy from other matched rabbits in aseptic conditions.

Technique of graft preservation and storage. Meniscal grafts, taken under aseptic conditions were stored in a deep-freeze at the temperature of -17 °C .

Surgical technique of meniscus transplantation. Experimental animals were anesthetized with a combination of Ketalar (0.2mg) and atropine sulfate (0.1mg/kg of body weight), together with antibiotic treatment (Tolycar, 0.5g). Through the medial parapatellar approach medial meniscectomy was done and a previously obtained meniscal graft was transplanted and sutured to the capsule and synovial membrane with 4-5 resorption sutures. The wound was closed in layers. The experimental animals were immobilized only with a fixed dressing that allowed resting on their leg as soon as they were free of pain. Antibiotics were prophylactically administered for 5 to 7 days following surgery.

The control group consisted of contralateral, knees of same animals where meniscectomy was performed without subsequent transplantation.

Clinical evaluation of the wound was made during dressing.

Radiological analysis. The operated knees were radiologically evaluated by analysis of anteroposterior and lateral views.

Macroscopic analysis (gross findings). After 2, 8 and 36 weeks (group I, II, III), the experimental animals were sacrificed with barbiturates, and, after medial

arthrotomy of the meniscus, cartilage and synovial membrane were evaluated macroscopically.

Pathohistological analysis. The entire meniscal transplants were excised, fixed in 10% of buffered formaldehyde solution and sections of 5µm thick specimens were stained by the following methods: hematoxylin-eosin (HE), periodic acid shift (PAS), Van Gieson, Paff Halmi, Masson Trichrome, Von Kosaa.

RESULTS

Clinical results: After the transplantation, the experimental animals were clinically evaluated. Their body weight and temperature were measured and the wounds were inspected. No signs of wound infection were recorded.

Radiological evaluation of antero-posterior and lateral views of operated knee joints revealed no degenerative changes within these groups in terms of subchondral sclerosis, cysts, osteophytes or narrowing of the intraarticular space (Fig.1).

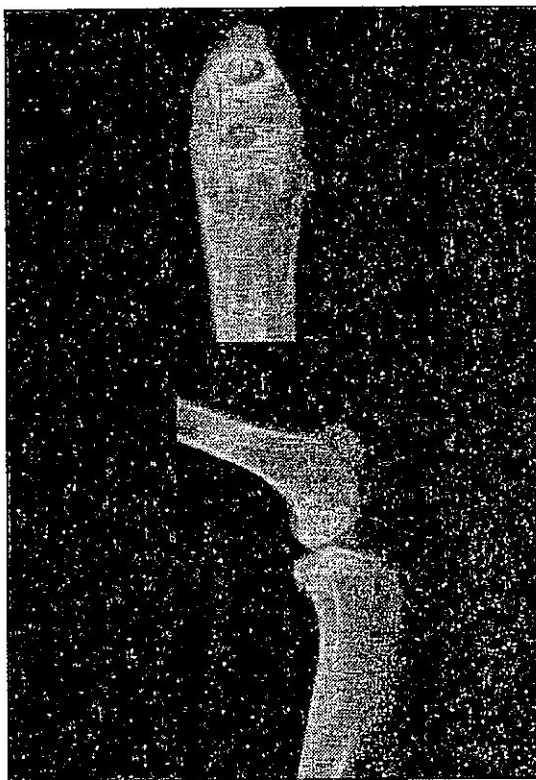


Figure 1. X-ray picture of operated knee joint, after 36 weeks, showing no degenerative changes.

In the control group, marked subchondral sclerosis and joint space narrowing were noted.

Gross findings: In the first group of experimental animals (sacrificed two weeks after surgery), macroscopic evaluation revealed a transplanted meniscus of normal appearance but modified much darker color and less shiny than normal.

In groups II and III (sacrificed after 8 and 36 weeks), respectively, the transplanted menisci had normal appearance, color and strength. There were no gross signs of infection. Degree I degenerative changes of cartilage were evident in two cases only after 4 to 5 months but there was no extensive destruction of cartilage.

Histological analysis showed a marked decrease of the cellular population, especially in the first group of experimental animals sacrificed after two weeks. Thus, collagen fibers were not oriented in a parallel manner and the lacunae were empty i.e. a low cell population was noted (Fig. 2).

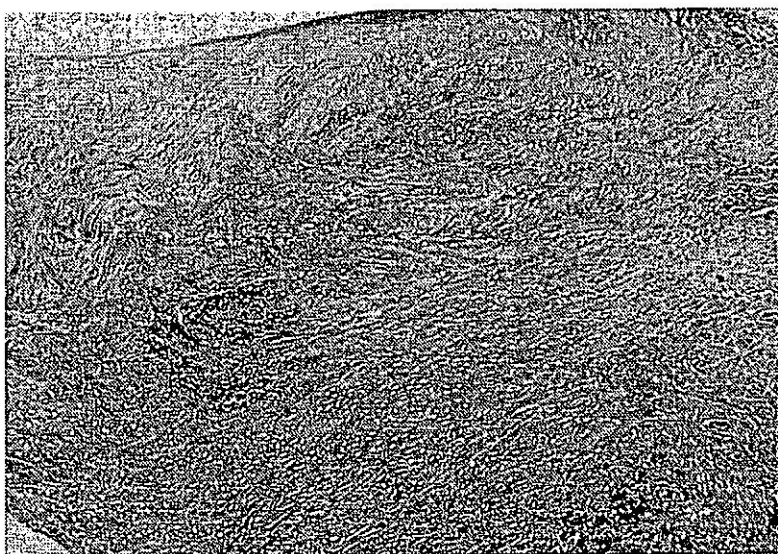


Figure 2. Meniscal allograft with marked cell depopulation and unoriented collagen fibers - two weeks after operation, (Masson Trichrome staining, 10X)

The synovial membrane was hypertrophic, but with no signs of inflammation or immune response. Histological evaluation of the cartilage underlying the transplanted meniscus showed no pathologic changes.

In the second group of experimental animals (sacrificed after 8 weeks), cell repopulation of the fibrochondroblast type had occurred, particularly at the meniscal circumference, with better orientation of immature collagen fibers (Von Kossas staining - red stain)- Fig 3.

There was fibroblast proliferation and the meniscal transplants and joint capsules were healed by fibrovascular scar tissue. The underlying bone was preserved.

In the third group of animals (sacrificed 36 weeks after surgery), cell repopulation was marked as well as revascularization at the meniscal-capsular

layer. Collagen fibers were young and immature (Fig. 4) and a small number of former collagen fibers remained.

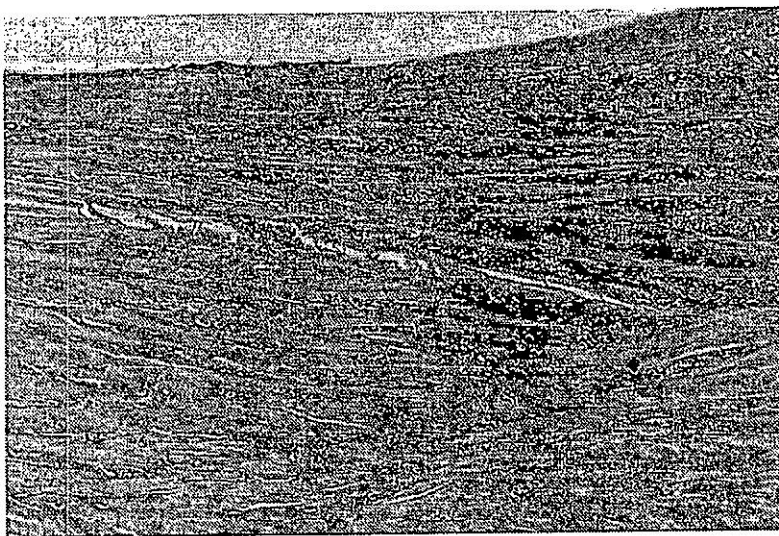


Figure 3. Specimen of the allograft with manifest cellular repopulation , 8 weeks after operation. (Hematoxylin - eosin - H&E, 25X)

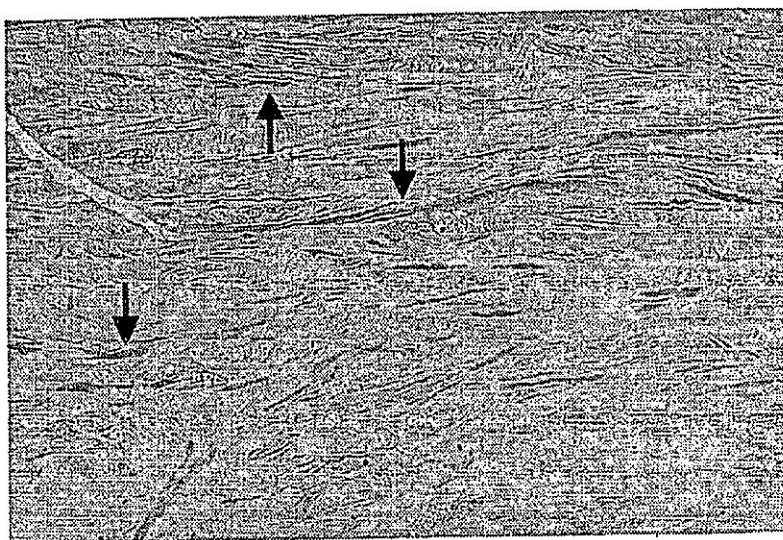


Figure 4. Young and immature collagen fibers in a specimen from the third group - 36 weeks after operation, (H&E 10X)




Figure 5. A few old collagen fibers remained (arrows), 36 weeks after operation, (Masson Trichrome staining, 10X)




Figure 6. Under the meniscal transplant (A), visible preserved subchondral cartilage (B) and normal bone (C), 36 weeks after operation, (H&E, 10 X)

Histological study revealed almost normal appearance of the meniscus with young connective tissue and preserved subchondral cartilage, with no signs of degenerative changes (Fig. 6). In the control group there was marked fibrillation and loosening of the cartilage tissue (Fig.7)



Figure 7. Control group (meniscectomy), 36 weeks after operation-meniscectomy, without meniscus replacement, showing gross chondral lesion (H&E, 10X)

DISCUSSION

The goal of meniscal transplantation is survival of the implanted allograft and achievement of the appearance and function of a normal meniscus, which would prevent cartilage destruction that may arise after total meniscectomy (Arnoczky *et al.*, 1989, Fabbriciani *et al.*, 1996, Kohn *et al.*, 1999).

Our results confirmed that there was no significant immune response. The meniscal tissue is considered "immunologically privileged" due to several factors: avascularization, the relatively small number of cells and their isolation from the host immune system (Fabbriciani *et al.*, 1996, Ochi *et al.*, 1995, Langer, 1975).

Considering the problem of obtaining a fresh meniscal allograft (time limited to 4-6 hours following the clinical death of the donor) and the high risk of infectious disease transmission, particularly HIV (Nemzek *et al.*, 1994, Verdonk, 1997, Buck *et al.*, 1988), the deep freezing storage technique becomes advisable. We have demonstrated that implant quality and utility of meniscal allograft stored in a deep-freeze are maintained.

In our study, significant cell repopulation of the meniscus and transformation of fibroblasts into chondroblasts as well as formation of new-young connective tissue had already developed after 8 weeks. Time-conditioned cell repopulation of allografts and formation of new collagen fibers have been reported by other authors (Mikic *et al.*, 1997, Fabbriciani *et al.*,

1997.). In our cases as well as in other authors studies (Aagaard *et al.*, 1999, Cummins *et al.*, 1997) the cartilage was protected in the area overlaid by the transplant. Special attention should be paid both to meniscal allograft positioning and the fixation technique and also to appropriate allograft size (Pollard 1995, Alhalki *et al.*, 1999, Lazovic *et al.*, a, b 1997.).

On the basis of this experimental study showing graft survival and maturation as well as the protected knee cartilage in a rabbit model it may be concluded that meniscus allografts stored by deep freezing are appropriate for application. Likewise, our statements agree with some limited and preliminary clinical trials (Nabeshima *et al.*, 1995 and Verdonk 1997, Goble *et al.*, 1999) in that the transplant survives through the process of remodelling and protects the underlying cartilage.

Address for correspondence:
 Dr. Aleksandar Lesic,
 Hadzi Melentijeva 8, 11000. Belgrade,
 Yugoslavia,
 e-mail Alelesic@Eunet.Yu

REFERENCES

1. Aagaard H, Jorgensen U, Bojsen M.F. 1999, Reduced degenerative articular cartilage changes after meniscal allograft transplantation in sheep. *Knee Surg Sports Traumatol. Arthrosc.* 7(3): 184 - 91
2. Alhalki MM, Howell SM, Hull ML. 1999, How three methods for fixing a medial meniscal autograft affect tibial contact mechanics. *Am J Sports Med* 27(3): 320 - 8
3. Arnoczky SP, Warren RF, McDevitt CA. 1989, Meniscal replacement using a cryopreserved allograft, an experimental study in the dog. *Clin Orthop Rel Research.* 252: 121- 8
4. Buck BE, Malinin TI, Brown MD. 1988, Bone transplantation and human immunodeficiency virus, an estimate of risk of acquired immunodeficiency syndrome. *Clin Orthop Rel Research*, 240: 129-136
5. Cummins JF, Mansour JN, Howe Z, Allan G. 1997, Meniscal transplantation and degenerative articular change: an experimental study in the rabbit. *Arthroscopy*, 13(4): 485 - 91.
6. Fabbriani C, Lucania L, Milano G, Panni SA, Evangelisti M. 1997, Meniscal allografts: cryopreservation vs deep-frozen technique, an experimental study in goats., *Arthroscopy* 5:124 -34.
7. Fukubayashi T, Kurosawa H. 1980, The contact area and pressure distribution pattern of the knee, a study of normal and osteoarthrotic knee joints. *Acta orthop Scand.* 51:871 - 9
8. Goble EM, Kohn D, Verdonk R, Kane SM. 1999, Meniscal substitutes - human experience, *Scan J Med Sci Sports*, 9(3): 147 - 57.
9. Kohn, Verdonk R, Aagaard H, Seil R, Dienst M. 1999, Meniscal substitutes- animal experience. *Scand J Med Sci Sports*, 9(3): 141 - 5.
10. Kuhn JE, Woylys EM. 1996, Allograft meniscus transplantation. *Clin Sports Med*, 15(3): 537 - 46.
11. Langer F, Czitrom A, Pritzker KP, Fross AE. 1975, The immunogenicity of fresh and frozen allogenic bone. *J Bone Joint Surg*, 57-A(2): 216 - 20
12. Lazovic D, Wirth CJ, Sieg A, Gosse F, Maschek H. 1997b, Effect of surgical technique on meniscus transplants. A histological, animal experiment study. *Unfallchirurg* 100(7): 541 - 6.
13. Mikic ZD, Brankov MZ, Tubic MV, Lazetic AB. 1997, Transplantation of fresh-frozen menisci- an experimental study in dogs. *Arthroscopy* 13(5): 579-83.
14. Nabeshima Y, Kurosaka M, Yoshiya S, Mizuno K. 1995, Effect of fibrin glue and endothelial cell growth factor on the early healing response of the transplanted allogenic meniscus: a pilot study. *Knee Surg Sports Traumatol Arthrosc.* 3(1): 34 - 8.
15. Nemzek JA, Arnoczky SP, Swenson CL. 1994, Retroviral transmission by the transplantation of connective-tissue allografts. An experimental study. *J Bone Joint Surg*, 76A(7): 1036 - 41.
16. Ochi M, Ishida O, Aisaku H, Ikuta Y, Akiyama M, 1995 : Immune response to fresh meniscal allografts in mice. *J Surg Res*, 58(5): 478 - 84.

17. Pollard ME, Kang Q, Berg EE. 1995, Radiographic sizing for meniscal transplantation. *Arthroscopy* 11(6): 684 - 7.
18. Tapper EM, Hoover NW. 1969, Late results after meniscectomy. *J Bone Joint Surg*, 51A(3): 517 - 26
19. Thompson W.O, Fu FH. 1999, The meniscus in the cruciate-deficient knee. *Clin Sports Med*, 12(4): 771 - 96.
20. Verdonk R. 1997, Alternative treatment for meniscal injuries. *J Bone Jont Surg*, 79B(5): 866 - 73

TRANSPLANTACIJA MENISKUSA U KOLENU KUNIĆA DUBOKO ZAMRZNUTIM MENISKALNIM ALOGRAFTOM, PATOHISTOLOŠKA SLIKA

LEŠIĆ A, SAVIĆ V, KRSTIĆ N, BUMBAŠIREVIĆ M i TATIĆ V

SADRŽAJ

Cilj ovog istraživanja je bio da se klinički, radiološki i histološki procene karakteristike duboko zamrznutog transplantata menuskusa na kolenu kunića. Ukupno je operisano osamnaest kunića, soja New Zeland i posmatrano u tri vremenske grupe: posle 2 nedelje (prva grupa), 8 nedelja (druga grupa) i posle 36 nedelja (treća grupa). Stanje životinje i operisanog kolena je praćeno klinički i radiološki, a po žrtvovanju je izvršena patohistološka analiza.

Kod operisanih životinja, nije bilo kliničkih i radioloških promena, za razliku od kontrolne grupe. Na histološkoj proceni meniskusa, u prvoj grupi (posle 2 nedelje) kolagena vlakna su bila neorijentisana sa izraženom ćelijskom depopulacijom, dok su posle 36 nedelja kolagena vlakna bila zrelija, sa značajnom ćelijskom repopulacijom.

Duboko zamrznuti meniskalni alograft pokazuje značajnu kolagenu remodelaciju i ćelijski oporavak a novi meniskus je štitio hrskavicu zgloba. Zbog toga je primena duboko zamrznutog alografta meniskusa opravdana u slučajevima gde nije moguće očuvati povredjeni meniskus.

